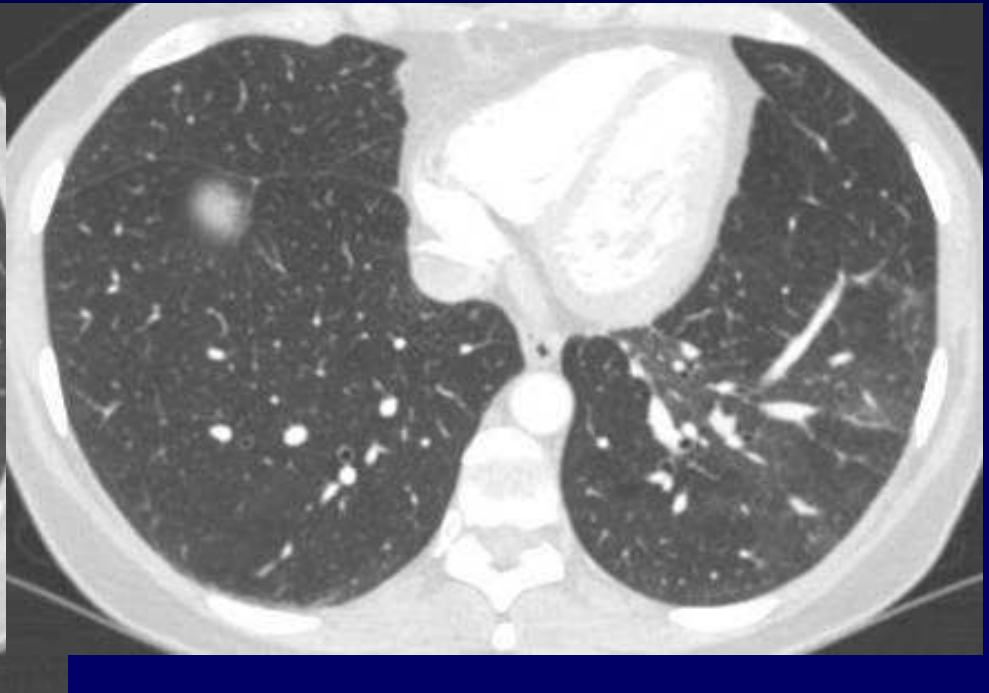
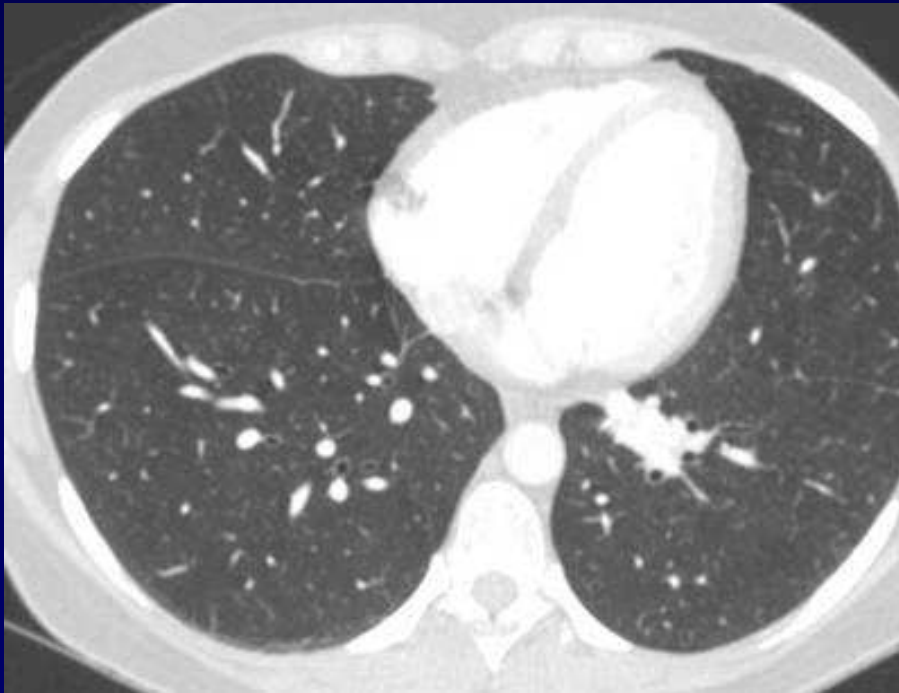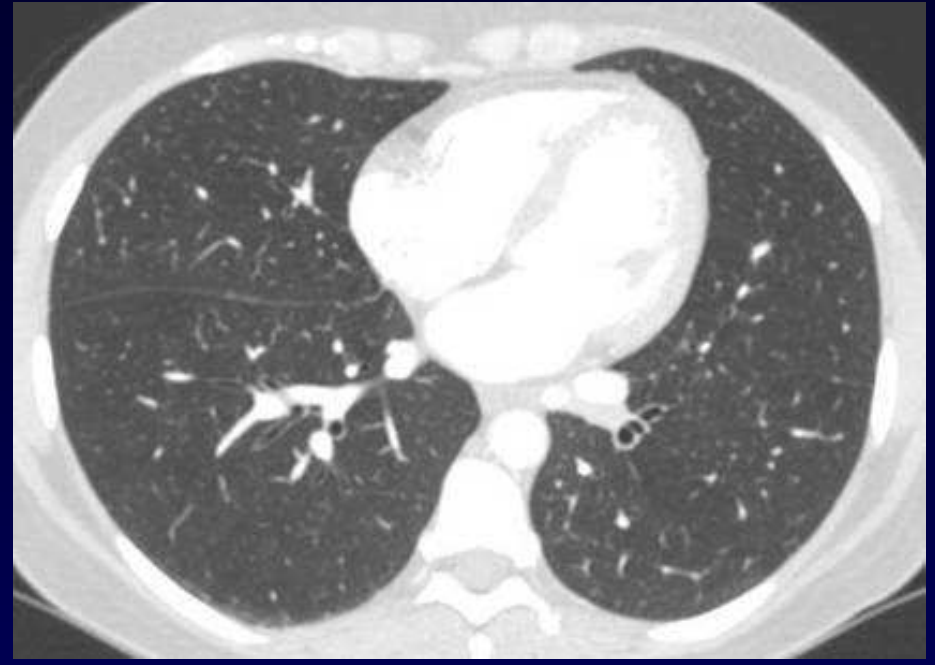

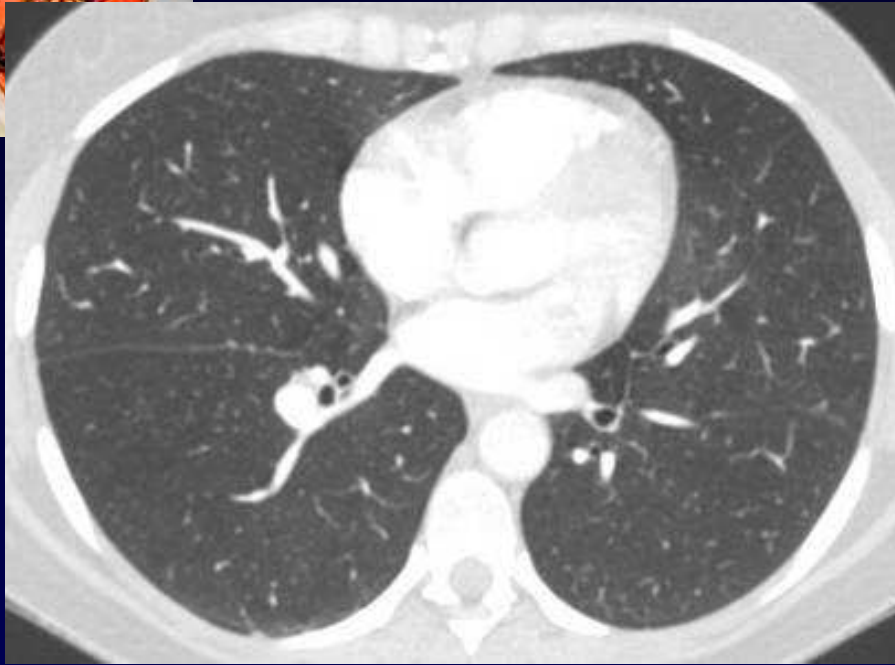
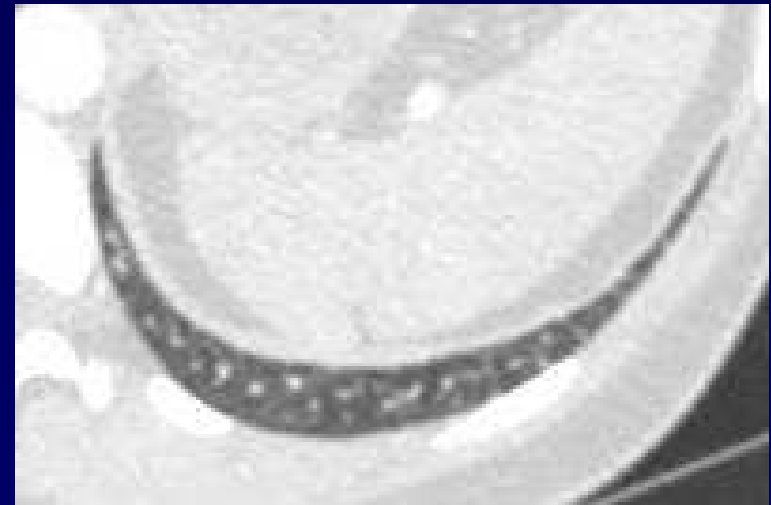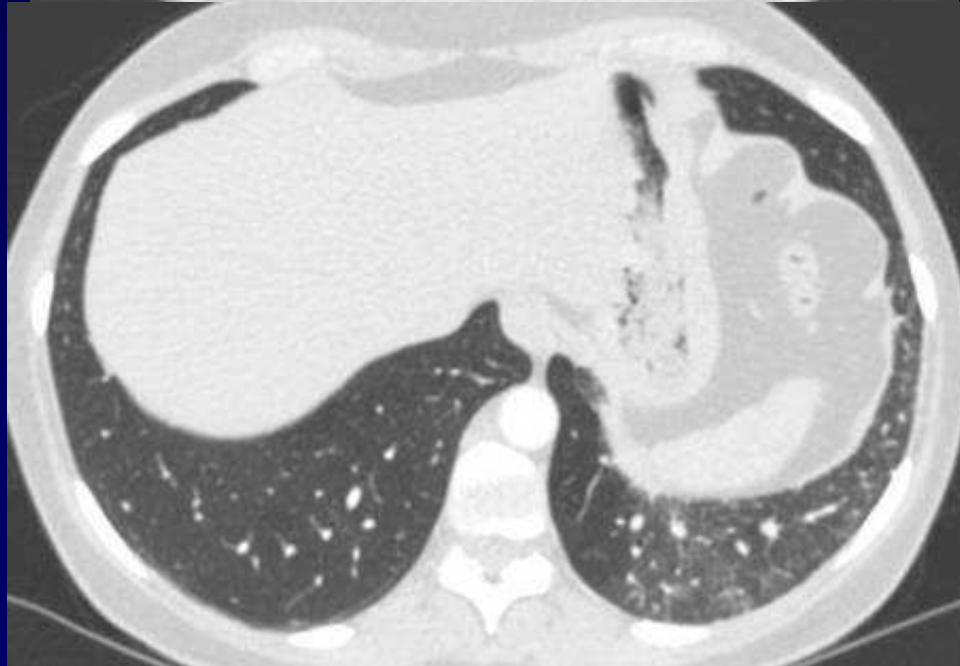


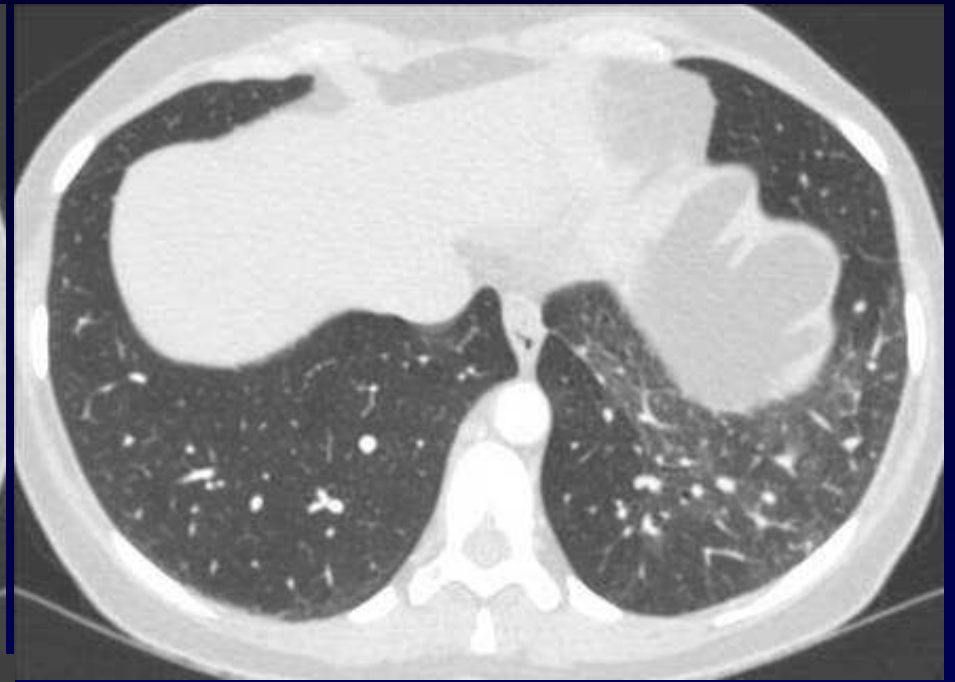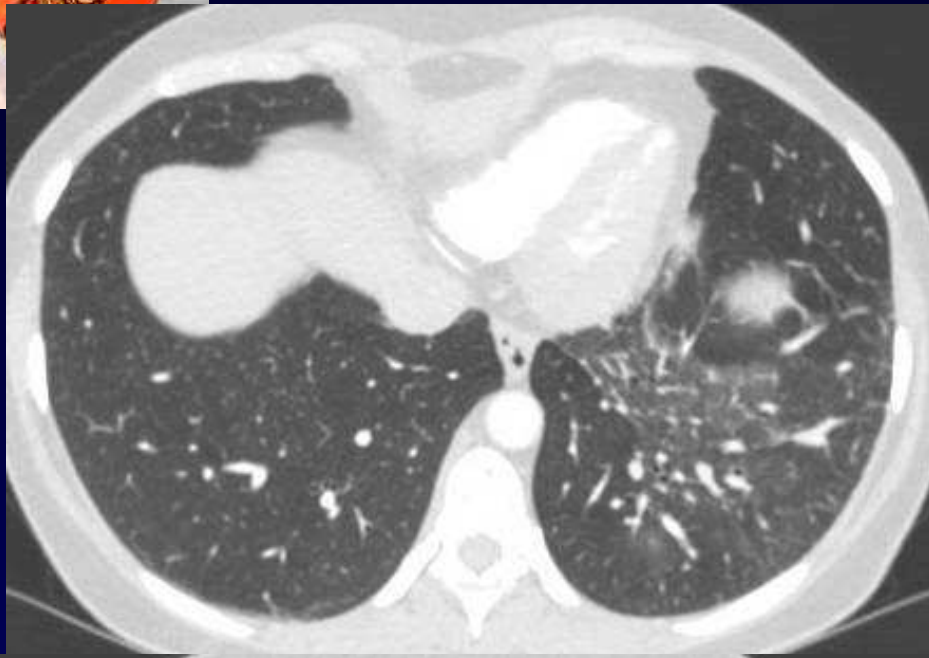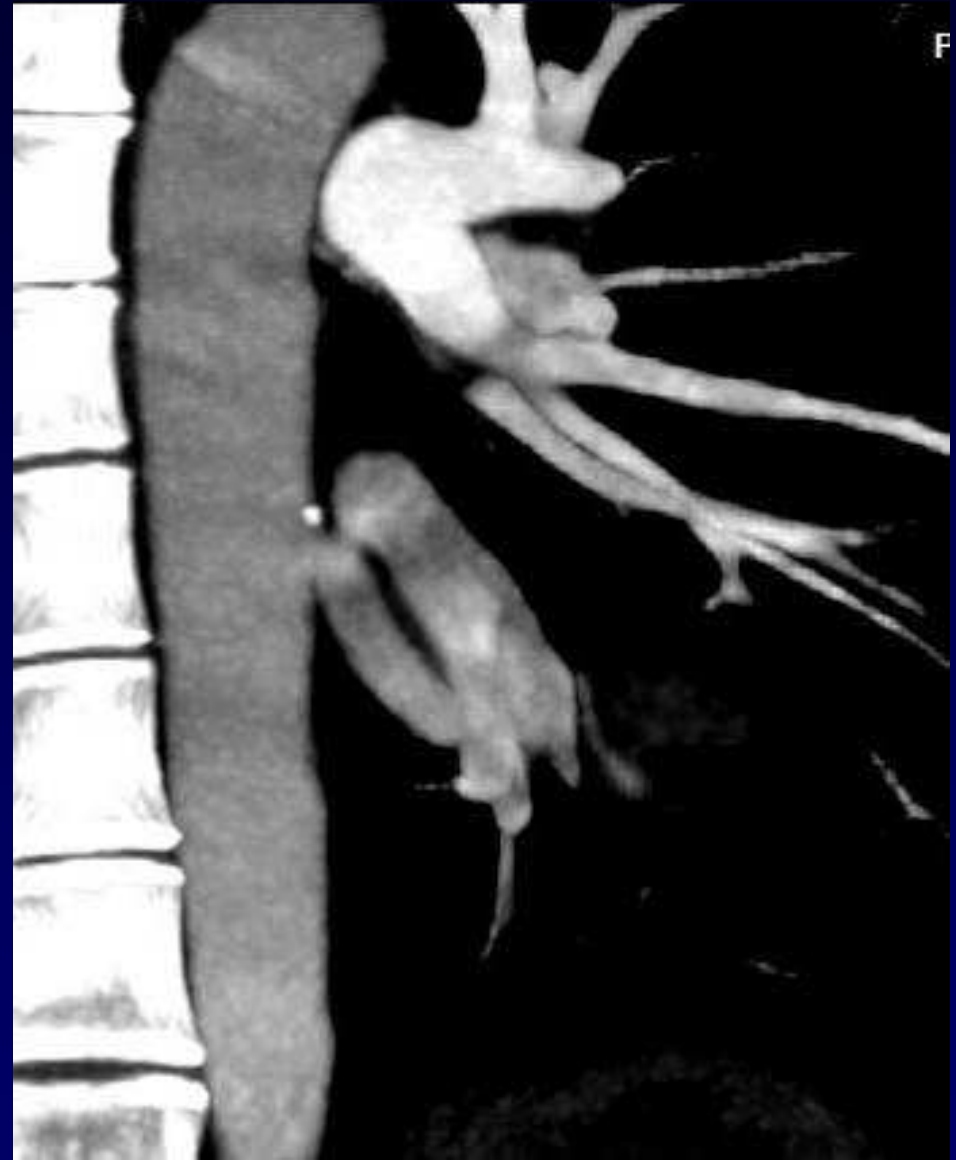
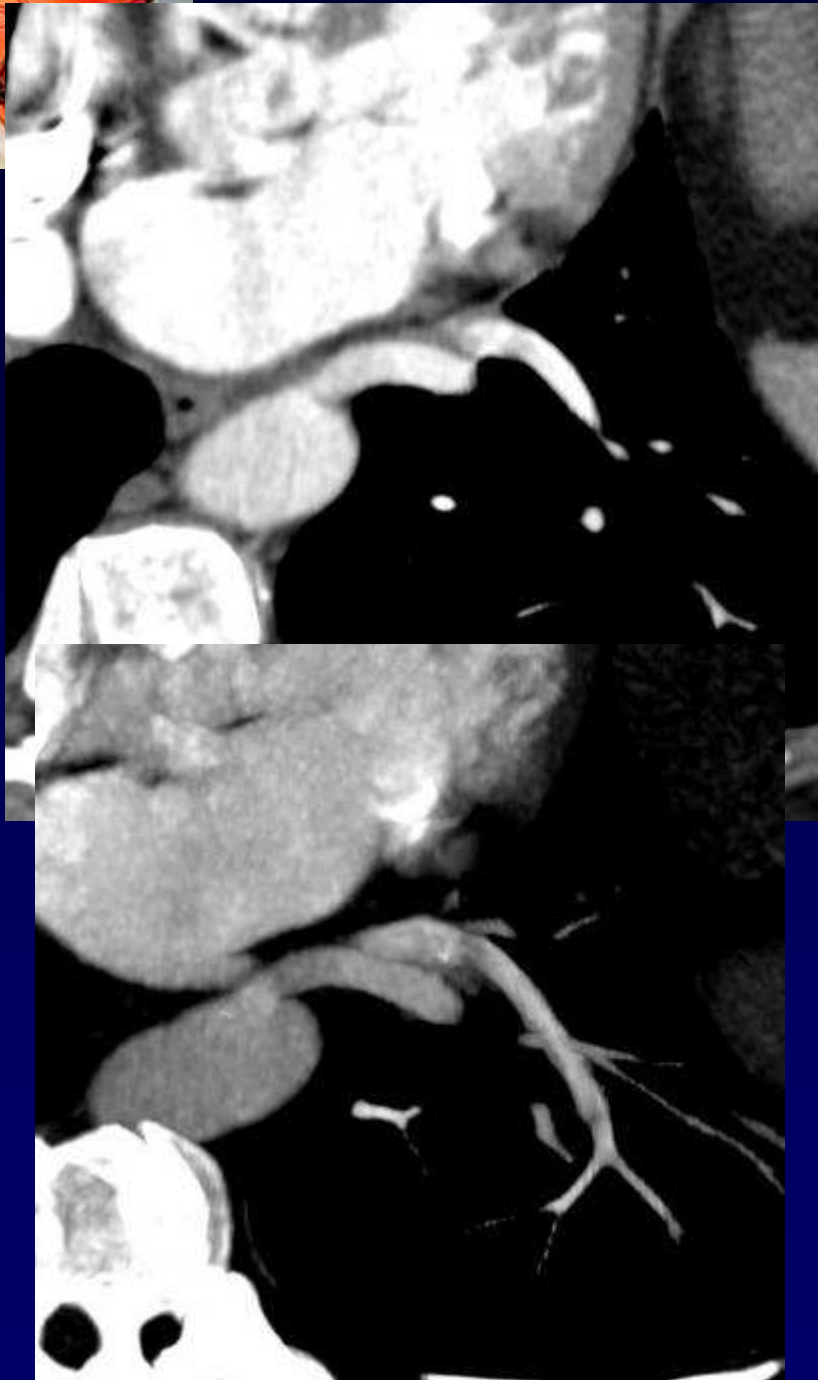
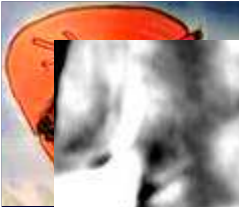Dossier 8

P FAJADET

- Homme de 45 Ans,
- Hémoptysie modérée de sang rouge nocturne et spontanée
- ATCD:
 - Tabac modéré sevré depuis 1990,
 - Hémoptysie 1990 Endoscopie + Radio thorax = N1e
 - Idem 2002 : « TDM = N1e »
- Bio, Gazo, B. Cardio = N1









Diagnostic ?



Diagnostic

**Séquestration intra-lobaire S 10G
vasculaire pure.**

Codage : Poumon – Cardiovasculaire - Congénital